



5196 Oxygen Saturation In Retinal Vein Occlusion



S.H. Hardarson^{1A}, R.A. Karlsson^{1B}, G.H. Halldorsson^{1B}, S.R. Joelsson^{1B}, T.Eysteinnsson^{1A}, J.A. Benediktsson^{1B}, J.M. Beach², E. Stefansson^{1A},
^AOphthalmology, ^BElectrical and Computer Engineering, ¹University of Iceland, Reykjavik, Iceland; ²Institute for Technology Development, Stennis Space Center, MS.

Purpose

Animal studies have shown that oxygen tension in the retina falls during retinal vein occlusion (RVO) and rises after laser treatment [1,2]. We used an automatic non-invasive retinal oximeter to measure the hemoglobin oxygen saturation in patients with RVO, before and after laser treatment.

Methods

Our automatic oximeter yields fundus images with 4 wavelengths of light simultaneously.

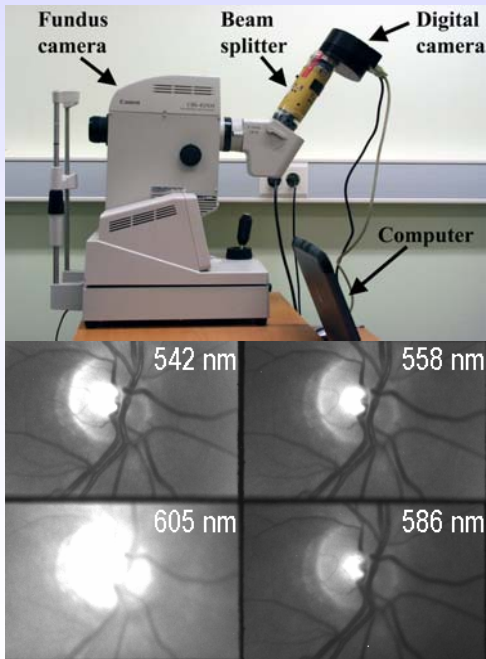


Figure 1. The retinal oximeter. Above: Components. Below: A typical output.

Specialized software automatically selects points on vessels and adjacent fundus for calculation of optical density ratios (ODRs). ODRs have an approximately linear inverse relationship with hemoglobin saturation (SatO₂) [3].

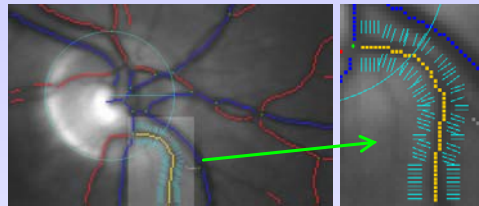


Figure 2. Automatic selection of measurement points

We performed oximetry in 7 patients with RVO. We measured the healthy fellow eye, and retinal venules outside and inside the occluded area in the RVO eye before and after laser treatment. Differences were analyzed with two-way ANOVA and Bonferroni post tests and with a paired t-test.

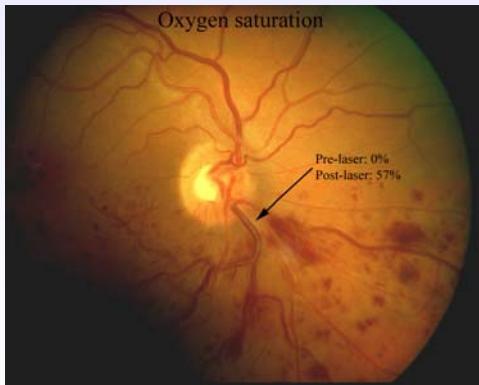


Figure 3. Hemivessel occlusion with pre- and post-laser measurements of oxygen saturation (see also same case in figure 6).

Results

The results are summarized in figure 4. The venular SatO₂ was 59±6% in healthy eyes (mean±SD; n=5), 60±12% in non-occluded areas of RVO eyes (n=4), 39±23% before laser in occluded venules (n=5) and 56±4% in occluded venules following laser treatment (n=5). Before laser the occluded venules had a significantly lower SatO₂ than healthy eyes or non-occluded venules of RVO eyes (p<0.05) and the SatO₂ was normalized by laser treatment.

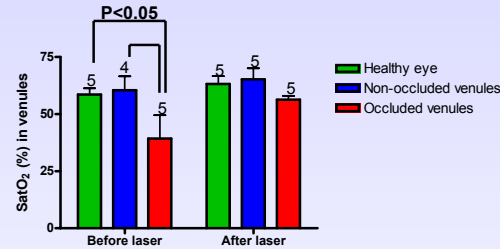


Figure 4. Oxygen saturation in three categories of venules. The figure on top of each column shows the number of venules measured

Figure 5 shows measurements on the 4 occluded venules that were measured both before and after laser treatment. The SatO₂ rose from 38±26% to 57±4% (mean±SD; p=0.24, paired t-test).

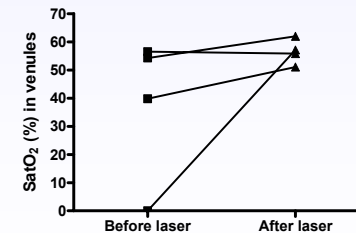


Figure 5. Four occluded venules measured before and after laser treatment.

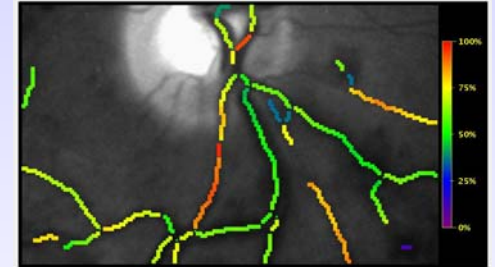
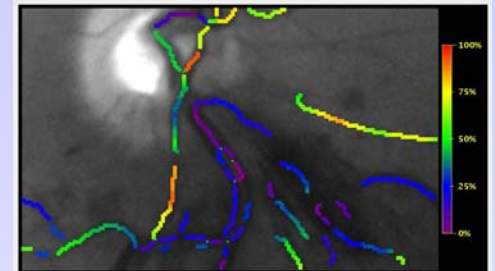


Figure 6. A color-coded map of the fundus, generated automatically with the oximetry software. This is the same fundus as in figure 3. Above: Before laser treatment. Below: After 3 sessions of laser treatment.

Conclusions

The automatic non-invasive retinal oximeter demonstrates decreased oxygen saturation in occluded retinal venules compared with healthy areas of the RVO eyes and healthy eyes. Laser treatment in RVO brings the oxygen saturation back within range of normal values.

References

1. Pournaras CJ, Tsacopoulos M, Strommer K, Gliodi N, Leuenberger PM. Scatter photocoagulation restores tissue hypoxia in experimental vasoproliferative microangiopathy in miniature pigs. *Ophthalmology* 1990;97(10):1329-33.
2. Stefansson E, Novack RL, Hatchell DL. Vitrectomy prevents retinal hypoxia in branch retinal vein occlusion. *Invest Ophthalmol Vis Sci* 1990;31(2):284-9.
3. Beach JM, Schweszer KJ, Srinivas S, Kim D, Tiedeman JS. Oximetry of retinal vessels by dual-wavelength imaging: calibration and influence of pigmentation. *J Appl Physiol* 1999;86(2):748-58.

Commercial relationship: S.H. Hardarson, Oxymap ehf., E. Oxymap ehf., P. R.A. Karlsson, Oxymap ehf., E. Oxymap ehf., P. G.H. Halldorsson, Oxymap ehf., E. Oxymap ehf., P. S.R. Joelsson, Oxymap ehf., E. T. Eysteinnsson, Oxymap ehf., I. Oxymap ehf., E. Oxymap ehf., P. J.A. Benediktsson, Oxymap ehf., I. Oxymap ehf., E. Oxymap ehf., P. J.M. Beach, Oxymap ehf., I. Oxymap ehf., P. E. Stefansson, Oxymap ehf., I. Oxymap ehf., E. Oxymap ehf., P.

Support: Icelandic Research Council, Icelandic Fund for Prevention of Blindness, University of Iceland Research Fund, Landspítali - University Hospital Research Fund.